

# Structural and physiological changes in tendinopathy.

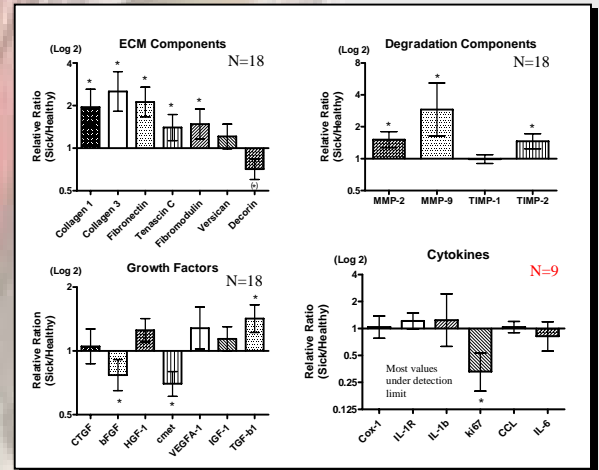
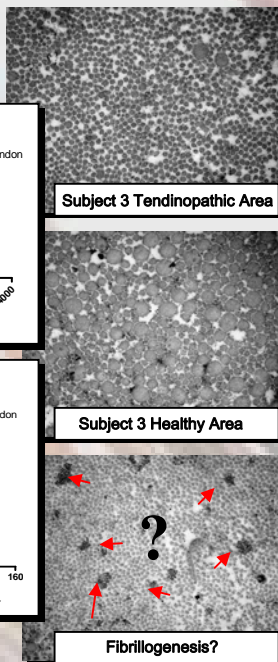
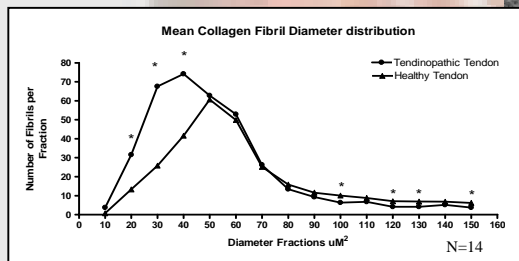
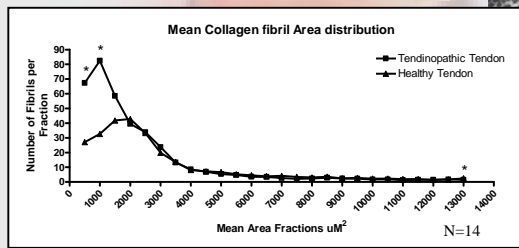
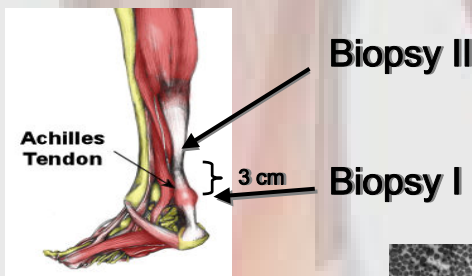
Pingel J., Fredberg U., Qvortrup K., Overgaard J., Schjerling P., Heinemeier K., Kjaer M. and Langberg H.



**Introduction:** Tendinopathy is a very common, painful and resistant disorder among both elite- and recreational athletes. In spite of the extent of the problem not much is known about the etiology and pathogenesis of tendinopathy. It is also still unclear to what extent inflammatory factors are involved in Tendinopathy.

**Aim:** The aim of the present study was to determine how tendinopathy affects the collagen structures and elucidate whether inflammatory factors are expressed in tendinopathic tissue.

**Design:** 32 Achilles tendinopathy patients were recruited and analysis of several gene expressions (N=18) and Transmission Electron Microscopy (N=14) were made.



## Results:

Several extracellular matrix factors and growth factors were significantly increased in tendinopathic tissue (Collagen 1, Collagen 3, Fibronectin, Tenascin C, TGF- $\beta$  and Fibromodulin) with Decorin and bFGF being significantly decreased, indicating an increased collagen synthesis in tendinopathy.

Additionally several proteinases were significantly increased (MMP-2, MMP-9 and TIMP 2) suggesting an increased degradation of the tissue.

No changes could be observed in inflammatory factors (CTGF, HGF, VEGF, IGF, COX-1, IL-1R, IL-1b, CCL and IL-6), since most values were under the detection limit.

Altogether these results indicate an increased collagen turnover in tendinopathy.

**Conclusion:** We conclude that several gene expressions are changed with tendinopathy indicating an increased collagen turnover in tendinopathy. No signs of inflammation could be detected supporting the notion that tendinopathy is an ongoing degenerative process.

A significant difference between the tendinopathic and the healthy collagen fibril diameter and mean area distribution was observed. The tendinopathic part of the tendon showed significant more fibrils per  $\mu\text{m}^2$  with a small diameter and mean area.